

THE GUANCHE MUMMY IN GÖTTINGEN RECENT RESEARCH AND FINDINGS

Oliver Gauert¹ and Birgit Grosskopf²

¹ Roemer- und Pelizaeus-Museum Hildesheim
Am Steine 1-2, 31134 Hildesheim, Germany
o.gauert@rpmuseum.de

² Johann Friedrich Blumenbach-Institut für Zoologie und Anthropologie
Abteilung Historische Anthropologie und Humanökologie
Georg August Universität Göttingen
Bürgerstr. 50, 37073 Göttingen, Germany
birgit.grosskopf@biologie.uni-goettingen.de

GAUERT, O. AND GROSSKOPF, B. (2021). The Guanche mummy in Göttingen recent research and findings. *Canarias Arqueológica*, 22: 159-173. <http://doi.org/10.31939/canarq/2021.22.16>

Abstract. The collection of the Anthropological Department of the University of Göttingen preserves a mummy from the pre-Spanish Guanche culture of Tenerife. It is the body of a woman, who had probably died before having reached the age of 40. The mummy is in a very good state of preservation. Many internal structures are still detectable inside the thoracic cavity and partly

even inside the abdominal cavity. The body does not show any traumatic conditions such as healed fractures. This may be an indication that the woman belonged to a privileged social class and was therefore exempt from hard work. The state of preservation is the result of quick desiccation after death. There is no evidence for any invasive mummification procedures.

Keywords. Guanche mummy, CT analysis, DNA analysis, Soft tissue preservation.

The Guanches were the indigenous inhabitants of the Canary Islands, in particular of the largest island, Tenerife. Initial settlement of the Canary Islands is thought to have originated from North Africa. This assumption is based mainly on

similarities between the few remnants of the Guanche language known until today and the Berber languages of North Africa. There is, however, now also genetic evidence, supporting a relationship with the Berber peoples of North Africa (Rodríguez-Varela *et al.* 2017). Based on archaeological findings, the Guanches' way of life is described as stone-aged and their diet was rich in meat and dairy products (Rodríguez-Martin, 1996). They produced ceramics, but had no knowledge of metal-working. They did not build ships, either. At the latest since the 3rd century onwards Tenerife was a very isolated place. Even contacts within the Canarian archipelago seem to have been extremely limited. The Guanches left some petroglyphs, but they had no true system of writing.

The Guanches used to mummify their dead, even though mummification was obviously limited to members of the upper classes. There are numerous accounts on mummification procedures throughout the history of the islands since the Spanish conquest¹. Their reliability is, however, in many cases questionable, since a number of reports seem to have been influenced more by the authors' *a priori* knowledge of Egyptian mummification practices than by their own experience (Méndez Rodríguez 2014, p. 53). Mummification generally did not include elaborate procedures comparable to those known from Egypt. The existence of invasive anthropogenic mummification is still being discussed (Aufderheide, 2003 p. 163; see also Rodríguez Martín & González Antón 1994; see also Álvarez Sosa & Morfini 2014). In the majority of cases, however, the preservation of the body was achieved mainly through desiccation, supported by additional measures such as washing with salt water and treatment with plant materials.

The dried mummies were then sewn into animal skins and stored in caves. There are reports indicating that some caves on the island contained very large numbers of mummies (for example, Ulbrich 2002; see also Rodríguez Martín & González Antón 1994).

The famous scientist Johann Friedrich Blumenbach (1752-1840) is considered to be one of the first mummy researchers (Di Biase-Dyson & Grosskopf 2019) and the founder of comparative anatomy and physical anthropology. As a professor in Göttingen, he taught for a long time and was the first curator of the "Königlich Academisches Museum". Through his many contacts (amongst them Sir Joseph

¹ Earliest reports date back to the 15th century. For a compilation and extensive discussion of the sources see Méndez Rodríguez 2014 or for a short overview see Gauert 2016.

Banks, Alexander v. Humboldt, Georg Thomas von Asch, and Johann Wolfgang v. Goethe) he was able to acquire numerous rare and scientifically valuable exhibition objects for the first museum of Göttingen. For this reason in 1802, he received a mummy belonging to a native inhabitant of Tenerife. Sir Joseph Banks, an English explorer who accompanied James Cook on his first trip in the mid-eighteenth century, received this mummy on Tenerife and sent it to Blumenbach.

In a letter dated February 24, 1802 he states: :“yesterday [...] delivered to Mr. Best, the Canarian mummy I promised to send to you, he has an opportunity in Forwarding some large Packages of the Duke of Cambridge, to send the mummy, which of Course I hope you will Receive safe & better & sooner than you could have done by any other mode of conveyance.” (Klatt 2015, p. 142).

Blumenbach was very pleased to be able to examine a Guanche mummy and wrote to Johann Wolfgang von Goethe on April 4th in 1802: “Eben bin ich mit der Untersuchung einer überaus merkwürdigen vortrefflich con-servirten Guanchen Mumie aus Tenerife (von den alten Ureinwohnern der Canarischen Inseln) beschäftigt die ich vorige Woche noch mit der Hülle von Ziegenfellen worin diese Leichen eingeschnürt worden, von Herrn Banks zum Geschenk erhalten habe.” (Klatt 2015, p 168/169). [Translation by B. Grosskopf: At the moment I am in the process of investigating a very remarkable and well-preserved Guanche mummy from Tenerife that was still wrapped in a cloak of goat skins, which I received last week as a gift from Mr. Banks].

ANTHROPOLOGICAL INVESTIGATIONS

The mummy, which belongs to an adult individual, has a total length (not body height) of 145 centimeters and is in a supine position. The body is tilted slightly to the left, lying on the leather in which it was originally wrapped according to the first descriptions. The ankles are tied together with a leather strap, and the arms are pressed close to the sides of the upper body and stretched parallel to the body with the right forearm lying across the pelvic area. The mummy is in a good state of preservation and the sunken and wrinkled surface texture of the soft tissue corresponds to the appearance typical for dry mummies.

Some superficial loss of substance is present. In addition, small hole-like defects are observable, which may have been caused by local rotting or possibly insects. Hair remains are no longer present. Some white crystalline deposits on the surface are believed to be salt crystals, since mummies were often stored in caves rich in sodium salts (Arnay-de-la-Rosa 2017).



Fig. 1. Guanche mummy from the Göttingen historical anthropology collection.

Significant damage to the mummy's lower abdominal cavity is present (Fig. 1). Blumenbach or other scientists may have made invasive examinations in this area at a later point in time, because there is no indication of damage on any of the first illustrations made by Blumenbach's son, Georg Heinrich Wilhelm, in March 1802 in Hannover. However, there is no record of invasive investigations.

Severe shrinkage due to drying around the lips has exposed the front teeth of the lower jaw. These exhibit heavy occlusal abrasion, which might otherwise suggest an older adult age. However, computed tomographic examinations showed no degenerative changes to the spine or other degenerative changes by age, indicating an estimated age at death of about 30-40 years. The individual therefore died at a younger age than was assumed after a previous examination in the 1980s by Herrmann (1987).

The sex of the mummy has already been determined by Blumenbach as female. This has also been confirmed by Herrmann (1987) and by the current CT examinations, in which a wide angle of the subpubic arc can be seen (Fig. 2). Additionally, small grooves on the inner part of the symphysis can be interpreted as birth (e.g. Suchey *et al.* 1979, Jugert *et al.* 2018). Even if a statement about the number of births cannot be made, this characteristic also confirms that it is the mummy of a woman.

RADIOCARBON DATING

Samples of soft tissue were extracted from the abdominal region for radiocarbon analysis. For the collection of the samples the already existing aperture was

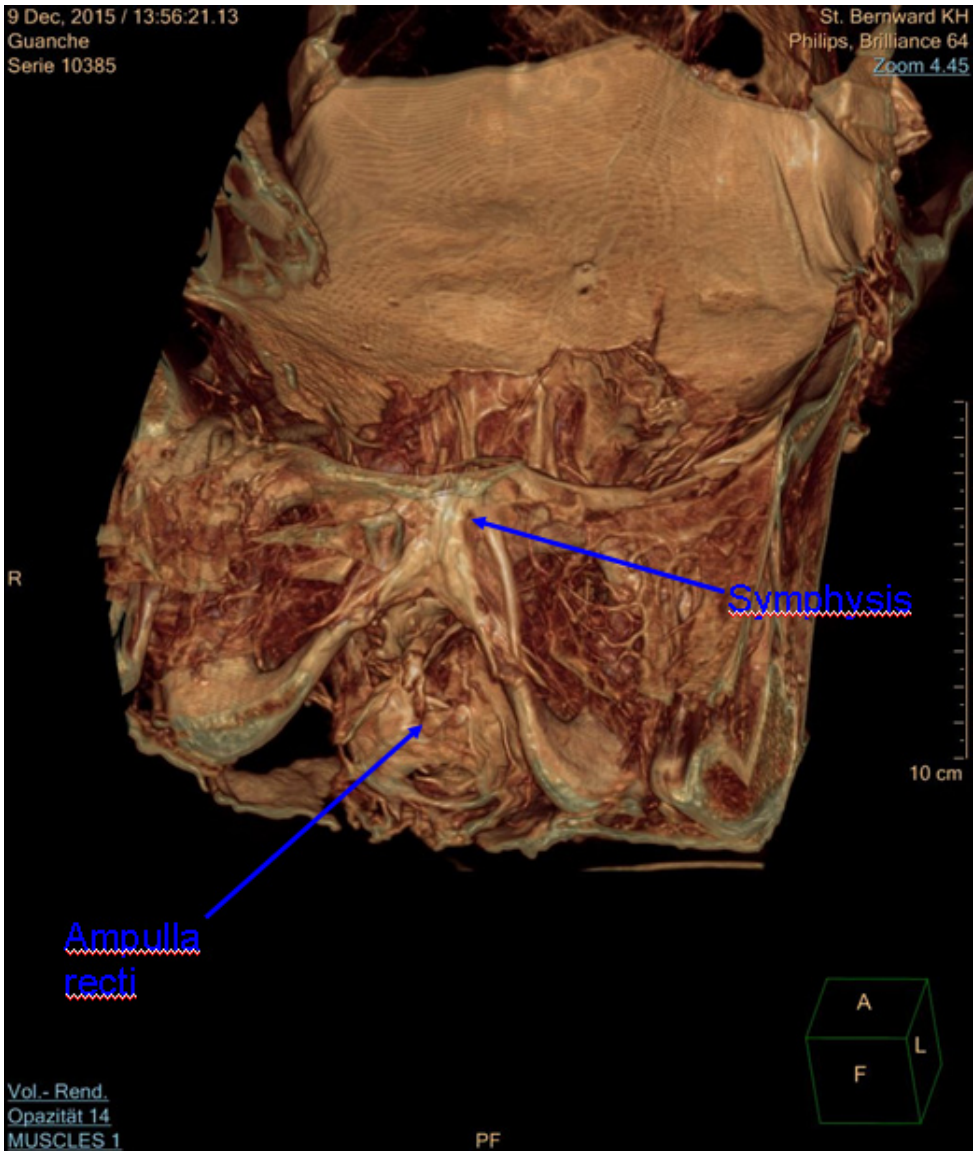


Fig. 2. Symphysis and ampulla recti.

used in order to avoid additional damage to the mummy. The results of radiocarbon analysis showed that the woman had died at the end of the 13th or the be-

ginning of the 14th century AD. Her life period thus falls into the final phase of the indigenous culture of Tenerife immediately before the Spanish conquest².

CT-ANALYSIS

The mummy has been subjected to CT investigation several times, first in 1984 and again in 2015 as part of the Hildesheim Mummy Research Project (using 3rd generation Multislice-64-CT / Philips-Brilliance)³. The original analysis back in the 1980s clearly demonstrated the presence of preserved soft tissue within the abdominal and thoracic cavities. Evisceration as part of the mummification process could therefore be excluded. It was, however, not possible to differentiate the different tissues and to identify individual anatomical structures, apart from the diaphragm and portions of the windpipe and the oesophagus (Hermann 1987, p. 108). Because of the superior spatial resolution and better soft-tissue differentiation the re-examination in 2015 allowed much better identification of anatomical details and tissue-characterization by analysing the whole high-resolution data-set. Therefore we could differentiate important tissue components and detect individual anatomical structures as the diaphragm and portions of the windpipe and aorta and even some single vertebral nerves and details of the trabecular bones of the vertebrae.

The new analysis was made using a state-of-the-art helical CT (Philips-Brilliance-64/ 0,625mm continuous-slice-thickness with overlapping axial reconstructions and multi-angle reformatting including generation of 3D-views with special workstations and advanced medical software-tools) in the Radiological Department of the St. Bernward Hospital Hildesheim.

² For a detailed discussion of the results of radiocarbon dating see: Gauert, Oliver/Grosskopf, Birgit/Holland, Bernhard. A mummy from the island of Tenerife in the Anthropological Department of the University of Göttingen. In: Schulz, Regine/Bayer, Christian/Gauert, Oliver (ed.). Proceedings of the International Conference on Comparative Mummy Studies Hildesheim 2016 (forthcoming)

³ First results were published in Schulz, Regine/Bayer, Christian/Gauert, Oliver (ed.). Mumien der Welt. Hildesheim 2016, 56-59; see also Gauert, Oliver/Grosskopf, Birgit/Holland, Bernhard. A mummy from the island of Tenerife in the Anthropological Department of the University of Göttingen. In: Schulz, Regine/Bayer, Christian/Gauert, Oliver (ed.). Proceedings of the International Conference on Comparative Mummy Studies Hildesheim 2016 (forthcoming).

The higher resolution revealed a good state of preservation of both abdominal and thoracic structures, clearly indicating that mummification was achieved only by means of desiccation and not involving any invasive procedures. The spinal column is complete and the integrity of the vertebrae is preserved. The degree of degradation is minute in the majority of the vertebrae and demonstrates a rather young age of death, even though some degradation is certainly recognizable as would be expected in an individual beyond the age of 30. The spinal cord or an accompanying structure – possibly the *dura mater* – can be pursued from the upper cervical spinal column down to the lumbar spine. Spinal nerves are still passing through the intervertebral foramina. Between the vertebrae the intervertebral discs are preserved and of these the *anulus fibrosus* is generally recognizable. Some substance between these bordering structures of the intervertebral discs might be dried residues of the *nucleus pulposus* (Fig. 3). The whole skeleton is intact and there is no evidence of pre- or postmortem fractures, which is remarkable given

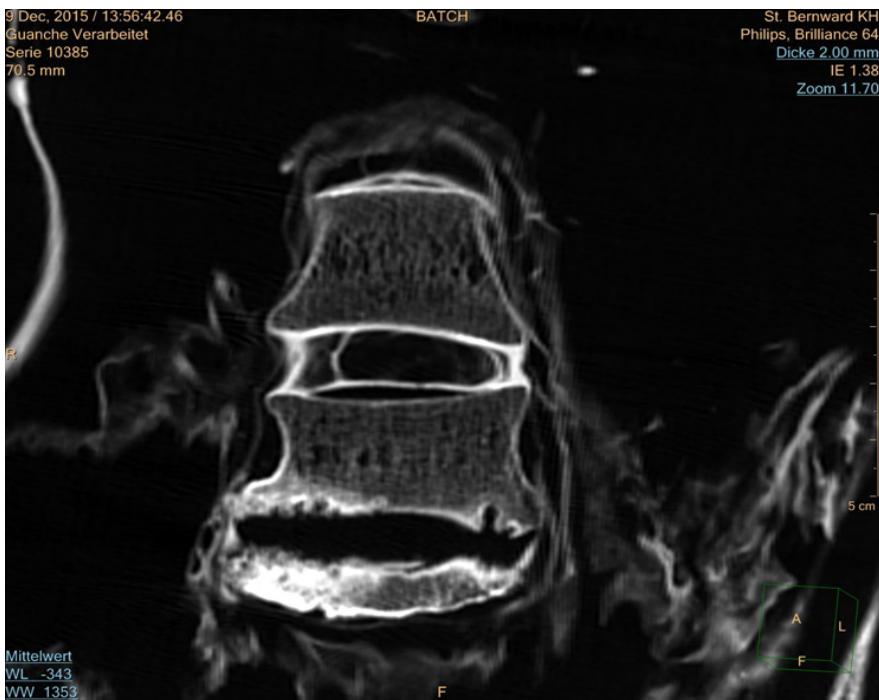


Fig. 3. Detail of the spinal column. Both the *disci intervertebrales* and degenerative changes are recognizable.

the high incidence of traumatic injuries found in human remains of the Guanche population (González Anton, Rodríguez Martín, Estévez González 1992; see also Rodríguez Martín & Martín Oval 2009). There are no signs of arthritic changes in the extremities either, supporting a rather young age of death.

Inside the thoracic cavity both the *pericard* of the heart and the lungs are preserved. Both the *aorta* and the *vena cava* are detectable and the *aorta* can be traced down to the diaphragm (Fig. 4). The *arcus aortae* is still complete and even smaller vessels can be recognized in the immediate proximity of the heart. These are most probably residues of the coronary arteries. The rib cage is completely intact along with adjacent soft tissue. Between the ribs the intercostal muscles are

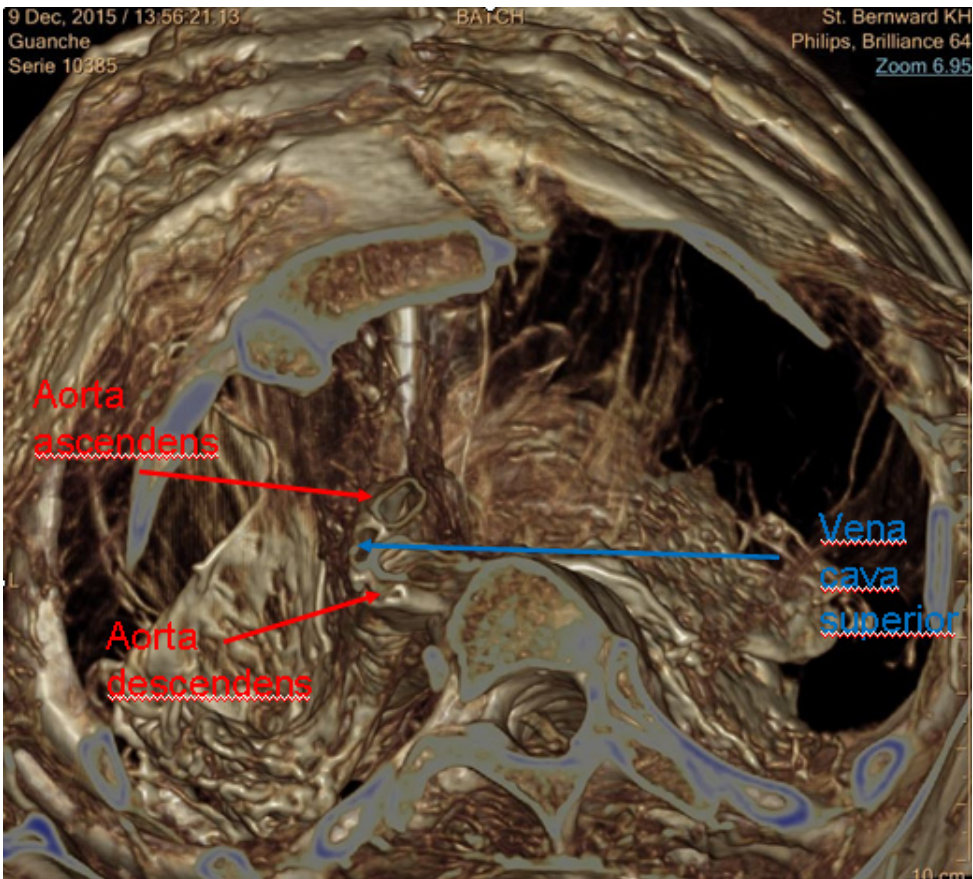


Fig. 4. Aorta and vena cava.

so well preserved that even the *musculi intercostales interni* and the *musculi intercostales externi* can be differentiated on the basis of the course of their fibers, which are running clearly in opposite direction. Even smaller vessels like the *arteria thoracica interna* can be visualized along both sides of the sternum. Not surprisingly the trachea, which due to its cartilage structure is highly resistant to decomposition processes, can be recognized in the immediate proximity of the spinal column (Fig. 5). Alongside the trachea we had expected to find remains of the oesophagus, which could, however, not be definitively identified, even though Herrmann has reported to have seen it in the framework of the first CT analysis in 1984 (Herrmann, 1987, p. 108). A new analysis with an even higher resolution CT might be able to indisputably detect this structure.

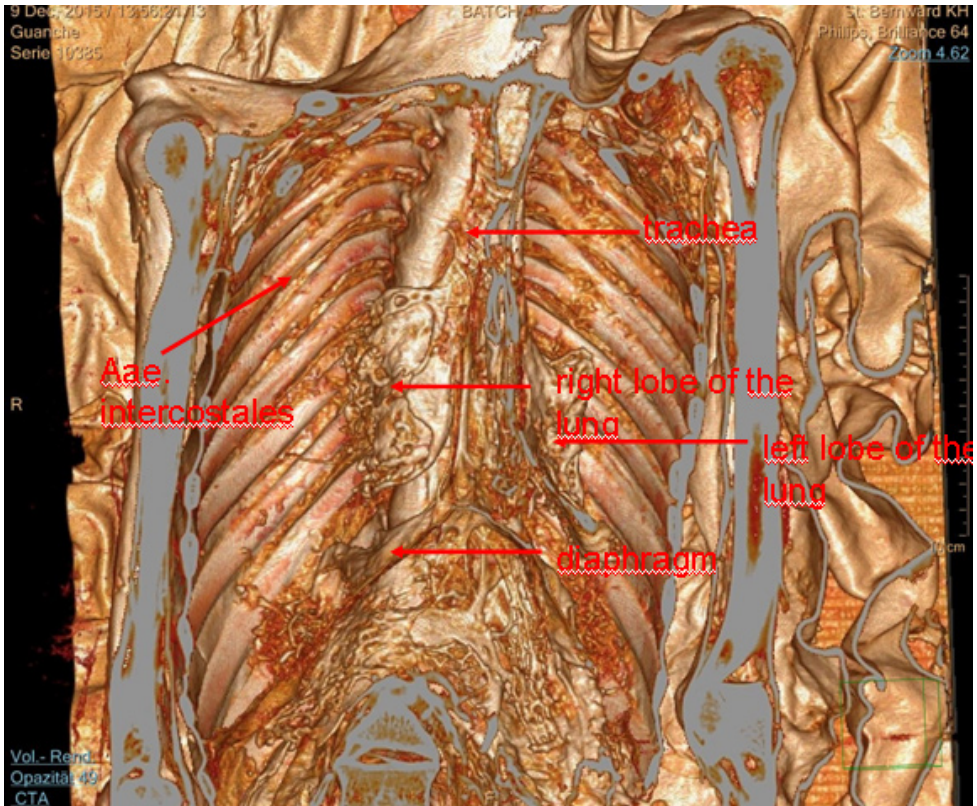


Fig. 5. Structures inside the thoracic cavity. Even smaller vessels like the *A. thoracica interna* could be visualized.

The diaphragm is well preserved, clearly defining the border between the abdominal and thoracic cavities. In the abdominal region structures are less well preserved, which is not surprising, given the high concentration of bacteria in this area and the resulting increased susceptibility for rapid decomposition of abdominal organs. Also the damages that were likely caused in the course of early investigations carried out by Blumenbach or later investigators contributed to the loss of tissue in this region of the body. The more amazing is the fact, that parts of the liver capsule and of the intestines are still detectable. The *ampulla recti* is entirely preserved, which is at least highly unusual.

Inside the cranial cavity no remains of the brain could be detected. The *dura mater* is, however, widely preserved. It may be possible that the brain liquefied during the early stages of decomposition and partly seeped away through the foramen magnum.

The only pathological condition found is an old inflammatory process in the pelvic region (Sacroiliitis), which was, however, not fatal and is not associated with the cause of death, for which no evidence has been found so far.

DNA ANALYSIS

Previous to the exhibition “Mumien der Welt” in Hildesheim, the mummy was sampled for molecular analysis and radiocarbon dating. Tissue samples were taken from the abdominal region for two reasons: First, the abdominal area already shows several destructions and, therefore, sampling could be done unobtrusively. Second, the sampling area was somewhat more protected from external contamination than e.g. the skin surface, since the region was located deep inside the abdomen. Unfortunately, the sampling area and sample material, respectively, seem to be rather unsuitable for molecular analysis.

Following death organic substances of the body autolytically decompose mainly due to endogenous enzymes. Tissues with a high content of organic material decompose much faster than those with a higher share of inorganic components (e.g. teeth are often well preserved, even though the rest of the skeleton is already decomposed). This is also evident for the state of endogenous DNA preservation, which appears to be generally better in the tooth roots or the petrous bone compared to other bones (e.g. Adler *et al.* 2011, Damgaard *et al.* 2015, Hansen *et al.* 2017) and, therefore, these elements are preferred for DNA sampling. However, in the case of the Guanche mummy the sample material ought to be spared and

the sampling position should have been as unobtrusive as possible. Therefore a decision was made not to extract material from the most suitable body regions.

All molecular analyses were conducted in a facility dedicated to ancient DNA (aDNA) analysis, following a rigorous cleaning protocol and established laboratory standards (e.g. Hummel 2003; Llamas *et al.* 2017).

Four tissue samples of approximately 50 mg each were taken from the abdominal region. In order to remove possible contaminations from the sample surface, two samples were incubated in 6 % sodium hypochlorite solution (Aug. Hedinger GmbH & Co. KG, Stuttgart, Germany) (e.g. Kemp and Smith 2005; Barta *et al.* 2013) for 5 minutes and washed in bidistilled water. As it is known that sodium hypochlorite solution not only removes exogenous DNA very effectively but also has a destructive effect on endogenous DNA (e.g. Kemp and Smith 2005), two tissue samples were only rinsed with bidistilled water. Every sample was dried overnight and afterwards minced finely. For the tissue lysis, every sample was incubated in ATL Buffer (Qiagen) and proteinase k in Tris/HCl (pH 7.5, 0.01 mol/L, 600 mAnson-U/mL, Merck) for 18 hours at 56 °C. Sodium dodecyl sulphate (10 mg/mL, Sigma-Aldrich®) was added to the suspension and incubated for 5 min at 65°C. After the total lysis of the samples, two different extraction protocols were applied: first, a manual DNA extraction and purification protocol with MinElute™ spin columns (Qiagen) and the QIAvac-System (Qiagen) following the manufacturer's protocol (e.g. Frischalowski *et al.* 2015, Flux *et al.* 2017); second, an automated DNA extraction protocol for large volumes (1 ml lysate) with the EZ1 Advanced (Qiagen) was performed using the DNA Investigator Kit (QIAGEN) according to the manufacturer's protocol. Additionally, with each protocol an extraction blank containing all chemicals used for lysis and extraction but no DNA was processed along with the samples. The elution volumes were 60 and 50 µl, respectively. In total, four DNA extracts (for each extraction protocol one sample, which was treated with sodium hypochlorite solution, and one, which was only rinsed with bidistilled water) were subjected to further analyses steps. For monitoring the DNA preservation and the extraction success, PCR-based amplification of autosomal Short Tandem Repeats (STR-typing) (Seidenberg *et al.* 2012) and a mitochondrial DNA sequence of the hypervariable region I (HVR I) was performed. The extraction blanks and no template controls (NTCs) were co-amplified in the PCRs to screen for possible contaminations in the extraction or PCR reagents. The amplification success was checked via agarose gel electrophoreses (2.5% agarose gel in 1xTBE buffer). Allele determination and sequence analysis

were performed by capillary electrophoresis via 3500 Series Genetic Analyzer (Applied Biosystems®) using POP-7™ Polymer (for 3500/3500xL Genetic Analyzers, Applied Biosystems®) and analyzed with the GeneMapper5 (Applied Biosystems®) and SeqA (Applied Biosystems®) software, respectively. The amplifications showed that low amounts of DNA were extracted only with the automated DNA extraction protocol. The STR-amplification failed almost completely. However, the amplification of the HVR I region was reproducibly successful for both automatically extracted samples resulting in very weak bands during agarose gel electrophoresis. The extraction blanks and NTCs showed no signals suggesting that the signals derived from the Guanche mummy ought to be authentic and not a result of an exogenous contamination. Initial evaluation of the sequencing results leads to the haplogroup M6, which has to be verified in future studies.

DISCUSSION

The state of preservation is extraordinarily good and is probably due to fast desiccation processes. It allows an assessment of soft tissue structures, which are only in few cases preserved (Rodríguez Martín & Martín Oval 2009, 279) and might be a basis for a prospective detailed paleopathological analysis. The good condition of the skeleton with little evidence of degradation is a clear indication for a relatively young age of death. This is supported by an almost complete lack of arthritic changes in the extremities. The overall good condition of the skeleton, which shows no injuries and also no defect healings is so exceptional, that it might be an indication that the woman belonged to a privileged class and was exempt from hard work.

Except for obvious signs of desiccation there is no evidence for any anthropogenic mummification procedures applied to the body. We found no incisions and no other indications for evisceration. Missing structures inside the abdomen are most probably the result of advanced decomposition and of post-mortem damage in modern times. The application of embalming materials to support the preservation of the body can, however, not be excluded.

CONCLUSION

The mummy in the collection of the Anthropological Department of the University of Göttingen is the body of a woman, who lived on the island of Tenerife

shortly before the Spanish conquest. She probably died before having reached the age of 40. Her body was artificially preserved. Mummification procedures, however, mainly involved desiccation and perhaps the use of embalming substances, which could so far not be detected. The current state of preservation is exceptional, making the mummy arguably one of the best preserved Guanche mummies still existing. Internal structures are still largely detectable, mainly inside the thoracic cavity, but some are even preserved inside the abdominal cavity. Pathological findings are limited to an old inflammatory process in the pelvic region (sacroiliitis) which was not fatal. The cause of death can therefore until now not be determined. Contrary to many other Guanche mummies, this body does not show any traumatic conditions such as healed fractures which may be an indication that the woman was part of a social class that was exempt from hard work and thus privileged. Further investigations including CT analysis using a higher resolution device and new genetic tests might even enhance our knowledge of this woman and help us broaden our understanding of the Guanche culture.

BIBLIOGRAPHY

ADLER C.J., HAAK W., DONLON D., COOPER A. & CONSORTIUM G. (2011). Survival and recovery of DNA from ancient teeth and bones. *Journal of Archaeological Science* 38:956-64

ÁLVAREZ SOSA, M. & MORFINI, I. (2014). *Tierras de Momias. La técnica de eternizar en Egipto y Canarias. La Orotava.*

ARNAY-DE-LA-ROSA, M., GONZÁLEZ-REIMERS, E., POU-HERNÁNDEZ, S., MARRERO-SALAS, E. & GARCÍA-AVILA, C. (2017). Prehispanic (Guanches) mummies and sodium salts in burial caves of Las Cañadas del Teide (Tenerife). *Anthropologischer Anzeiger*, 74: 143-153.

AUFDERHEIDE, A.C. (2003). *The Scientific Study of Mummies.* Cambridge.

BARTA, J.L., MONROE, C. & KEMP, B.M. (2013). Further evaluation of the efficacy of contamination removal from bone surfaces. *Forensic Science International* 231: 340–348.

DAMGAARD, P.B., MARGARYAN, A., SCHROEDER, H., ORLANDO L., WILLERSLEV, E. & ALLENTOF, M.E. (2015). Improving access to endogenous DNA in ancient bones and teeth. *Scientific Reports* 5: 11184.

DI BIASE-DYSON, C. & GROSSKOPF, B. (2019). Johann Friedrich Blumenbach (1752-1840) - Mumienforscher Vor-ägyptologischer Zeit. In: „Steinschrift und

Bibelwort“ Ägyptologen und Koptologen in Niedersachsen, Hrsg. Arp-Neumann J. & Gertzen T. L. in TA-MEHU. Ägyptologie in Norddeutschland 2: 93-98.

FLUX, A.L., MAZANEC, J., STROMMENGER, B., HUMMEL, S. (2017). Staphylococcus aureus Sequences from Osteomyelitic Specimens of a Pathological Bone Collection from Pre-Antibiotic Times. Diversity 9: 43.

FRISCHALOWSKI, M., SEIDENBERG, V., GROSSKOPF, B., WULF, F.-W. & HUMMEL, S. (2015). Molekulargenetische Untersuchung des Verwandtschaftsverhältnisses von möglichen Mutter-Kind-Bestattungen aus dem frühneuzeitlichen Eldagsen. Nachrichten aus Niedersachsens Urgeschichte, 84: 193–206.

GAUERT, O. (2016). Die Mumien der Guanchen. Von den Berichten der frühen Chronisten zu den Ergebnissen der modernen Forschung. Antike Welt 6: 25-29.

GAUERT, O., GROSSKOPF, B. & HOLLAND, B. A mummy from the island of Tenerife in the Anthropological Department of the University of Göttingen. In: Schulz, R., Bayer, C. & Gauert, O. (eds.). Proceedings of the International Conference on Comparative Mummy Studies Hildesheim 2016 (forthcoming)

GONZÁLEZ ANTÓN, R., RODRÍGUEZ MARTÍN, C. & ESTÉVEZ GONZÁLEZ, F. (1992). Bioantropología de las Momias Guanches. In: Munibe Supl. 8: 51-61.

HANSEN HB, DAMGAARD P. B., MARGARYAN A., STENDERUP J., LYNNERUP N., WILLERSLEV E. & ALLENTOFT M.E. (2017) Comparing Ancient DNA Preservation in Petrous Bone and Tooth Cementum. <https://doi.org/10.1371/journal.pone.0170940>

HERRMANN, B. (1987). Eine Guanchen-Mumie aus der anthropologischen Sammlung Johann-Friedrich Blumenbachs. In: Beuermann, G., Hirsche, M., Hunger, U., Jahnke, H., Schellhorn, R., Smend, R., Unverfehrt, G. & Wellenreuther, H. (eds.), 250 Jahre Georg-August-Universität Göttingen. Ausstellung im Auditorium 19. Mai-12. Juli 1987. Göttingen, 108-110.

HUMMEL, S. (2003). Ancient DNA Typing: Methods, Strategies and Applications; Springer Science & Business Media: New York, NY, USA.

JUGERT F., HUMMEL S. & GROSSKOPF B. (2018): Investigations on the Relation between Birth Trauma and Lesser Pelvic Size in Females of a Medieval Gravesite from Lübeck. Anthropologischer Anzeiger (Journal of Biological and Clinical Anthropology) 75/2, 141-153.

KEMP, B. M. & SMITH, D. G. (2005). Use of bleach to eliminate contaminating DNA from the surface of bones and teeth. Forensic Science International 154: 53-61.

KLATT, N. (2015). Brosamen zur Blumenbach-Forschung, Band 7. Norbert Klatt Verlag, Göttingen, Elektronische Ressource.

LLAMAS, B., VALVERDE, G., FEHREN-SCHMITZ, L., WEYRICH, L.S., COOPER, A. & HAAK, W. (2017). From the field to the laboratory: Controlling DNA contamination in human ancient DNA research in the high-throughput sequencing era. *STAR: Science & Technology of Archaeological Research* 3: 1-14.

MÉNDEZ RODRÍGUEZ, D.M. (2014). Momias, xaxos y mirlados. Las narraciones sobre el embalsamamiento de los aborígenes de las Islas Canarias (1482-1803). La Laguna.

RODRÍGUEZ MARTÍN, C. & GONZÁLEZ ANTÓN, R. (1994): Momias y momificación en las islas canarias prehispanicas. *Eres* 5: 117-131.

RODRÍGUEZ MARTÍN, C. & MARTÍN OVAL, M. (2009). Guanches. Una historia bioantropológica. Santa Cruz de Tenerife.

RODRÍGUEZ-MARTÍN, C. (1996): Guanche Mummies of Tenerife (Canary Island): conservation and scientific studies in the CRONOS Project. In: *Human Mummies, A Global Survey of their Status and the Techniques of Conservation*, Spindler, K., Wilfing, H., Rastbichler-Zissermig, E., ZurNedden, D. & Nothdurfter, H. (Eds.), Springer Science & Business Media Verlag.

RODRÍGUEZ-VARELA, R., GÜNTHER, T., KRZEWIŃSKA, M., STORÅ, J., GILLINGWATER, T. H., MACCALLUM, M., ARSUAGA, J. L., DOBNEY, K., VALDIOSERA, C., JAKOBSSON, M., GÖTHERSTRÖM, A. & GIRDLAND-FLINK, L. (2017). Genomic Analyses of Pre-European Conquest Human Remains from the Canary Islands Reveal Close Affinity to Modern North Africans. *Current Biology* 27: 3396-3402.

SCHULZ, R., BAYER, C. & GAUERT, O. (eds.) (2016). *Mumien der Welt*. Hildesheim

SEIDENBERG V., SCHILZ F., PFISTER D., GEORGES L., FEHREN-SCHMITZ L. & HUMMEL S. (2012). A new miniSTR heptaplex system for genetic fingerprinting of ancient DNA from archaeological human bone. *Journal of Archaeological Science* 39: 3224-3229.

SUCHEY, J.M., WISELEY, D.V., GREEN, R.F. & NOGUCHI, T.T. (1979): Analysis of Dorsal Pitting in the Os Pubis in an Extensive Sample of Modern American Females. *American Journal of Physical Anthropology* 51: 517-540.

ULBRICH, H.-J. (2002). *Tod und Totenkult bei den Ureinwohnern von Tenerife (Kanarische Inseln).*- *Almogaren XXXII-XXXIII / 2001-2002* (Institutum Canarium), Wien, 107-120.

